

## EQUINEW FES 310

### Clinical Cases

Clinical cases are examples of injuries that have been successfully treated with FES. Specific cases were selected because they were treated exclusively with the FES modality and have documentation of the treatment progress. These examples are offered only as an overview of a specific case, which may or may not apply to another similar case. Each clinical case will provide specific issues unique to that particular horse.

“German”

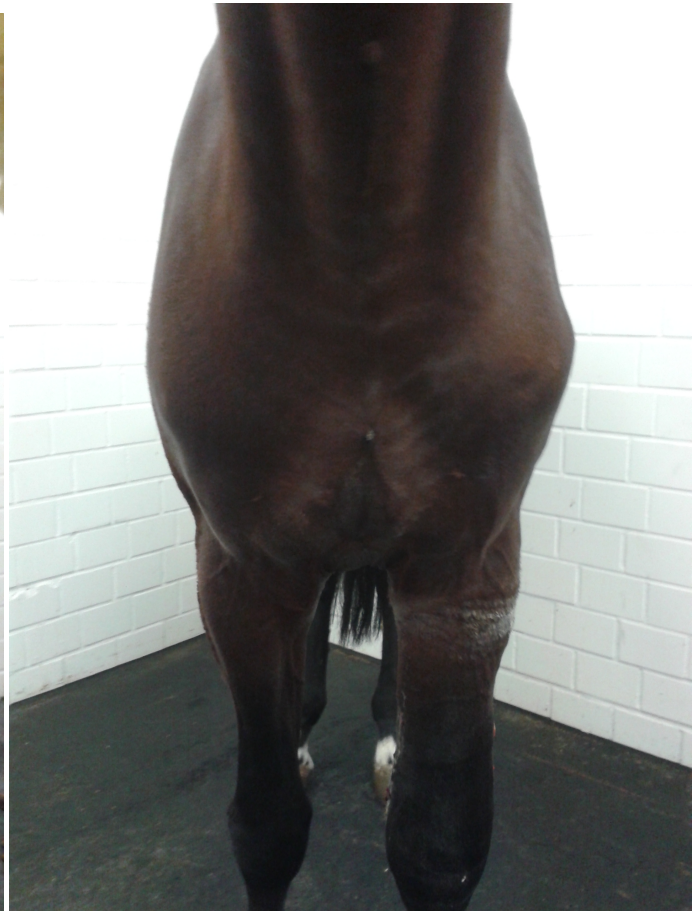
9-yr old Warmblood gelding

**Severe Left Shoulder Atrophy**

**5 FES Treatments** to infraspinatus and supraspinatus and **2 FES Treatments** to the thorax over **9 days**



PRE FES



POST 7 FES Treatments