

EQUINEW FES 310

Clinical Cases

The clinical cases outlined are examples of injuries that have been successfully treated with FES. Specific cases were selected because they were treated exclusively with the FES modality and have documentation of the treatment progress. These examples are offered only as an overview of a specific case, which may or may not apply to another similar case. Each clinical case will provide specific issues unique to that particular horse.

“Klass”

9-year old mare – Hunter/Jumper

Deep Digital Flexor Tendon Lesion

20 FES Treatments on legs

9 FES Treatments on top line

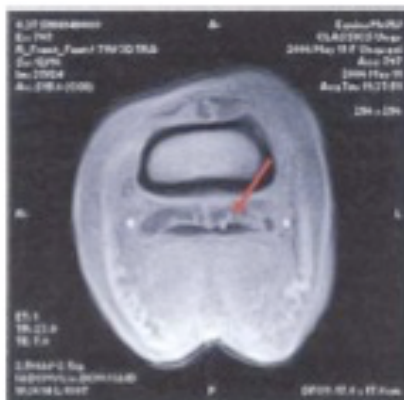Until sound for jumping competitions

SUMMARY: MRI results indicated lesion of right fore deep digital flexor tendon. Upon initial examination mare was uncomfortable showing Grade 3/5 lameness on right front under saddle. Right scapula was significantly dropped relative to left scapula when standing. L2 – S4 was extremely tender to palpation. Gluteals were also extremely reactive to palpation, especially on right. When riding, mare dropped right shoulder excessively in turns, was stiff to right bend through torso and leaned heavily on right rein. Mare returned to jumping after 9 months of FES treatments, and had follow up treatments every 6 months for three more years. No further treatments have been made since the end of the 3-year follow up and the mare continues to be sound for jumping.

MRI Results

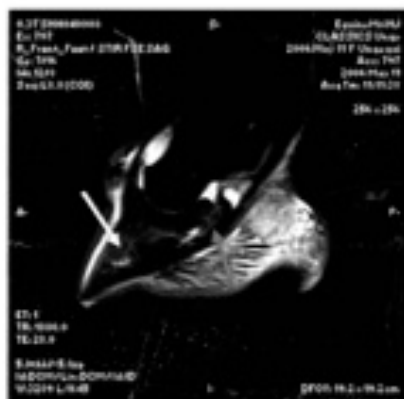
May 11, 2006

RF/LF foot



T1W 3D Transverse, RF

Arrow indicates increased signal at the dorsal margin of the deep digital flexor tendon lesion. This is the lesion of the deep digital flexor tendon.

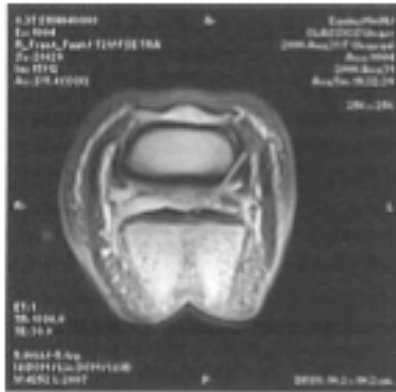

STIR FSE Sagittal, RF

The red arrow indicates increased fluid in the navicular bone. Yellow arrow indicates abnormal fluid accumulation of the coffin bone. This represents edema/contusion, secondary to abnormal gait due to pain stemming from the deep digital flexor tendon.

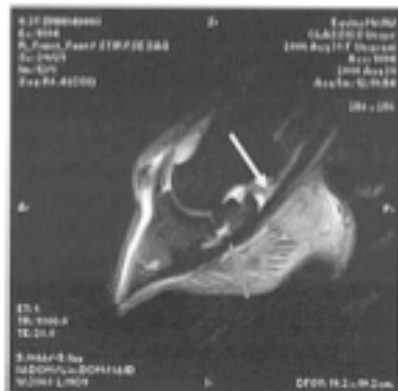(over)

AUGUST 31, 2006
RF foot



T2W FSE Transverse

Arrow indicates increased signal at the dorsal margin of the deep digital flexor tendon lesion. This is the lesion of the deep digital flexor tendon with tissue proliferation/adhesions formed between the DDFT, navicular bursa, and collateral sesamoidean ligament.



STIR FSE Sagittal

The red arrow indicates a focal region of increased fluid in the navicular bone (edema of the medullary cavity has resolved). The edema of the coffin bone has resolved. Yellow arrow indicates improvement of the amount of fluid present in the navicular bursa (improved bursitis).

Notes from 8/31/06 report

“The tendon lesion has improved on T2-weighted and STIR images and does not contain fluid”,
“the tendon lesion does not appear active”