

## EQUINEW FES 310

### Clinical Cases

Clinical cases are examples of injuries that have been successfully treated with FES. Specific cases were selected because they were treated exclusively with the FES modality and have documentation of the treatment progress. These examples are offered only as an overview of a specific case, which may or may not apply to another similar case. Each clinical case will provide specific issues unique to that particular horse.

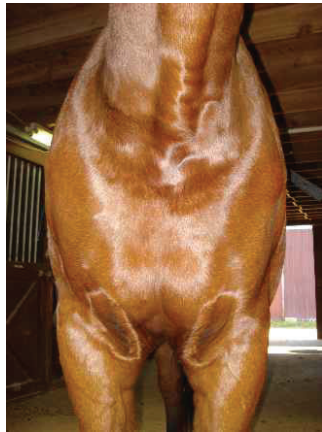
“Ariel”

7-yr old Warmblood gelding

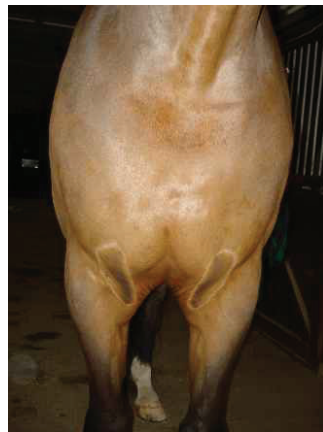
**Right Shoulder Atrophy**

**6 FES Treatments over 3 months**    2 sets of 3 treatments every 6 weeks

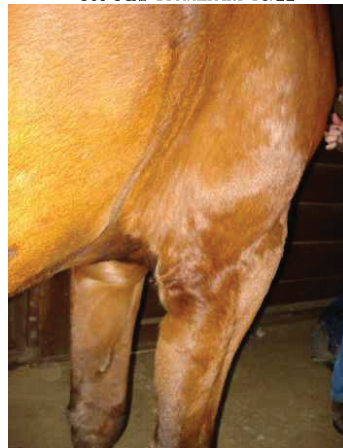
**SUMMARY:** Upon examination the gelding showed distinct atrophy of the right shoulder muscles, specifically the triceps. The horse was grade 4 lame in the right front and had previous problems with the ligaments of the right front coffin confirmed with MRI. At the time of examination, the ligament problem was resolved based on MRI images, but the lameness continued. Injections of the coffin and fetlock did not resolve the lameness. 6 FES treatments were given over a period of 3 months. The treatments were given in sets of 3, with 6 weeks between sets. During the first set for treatments, 2 FES treatments were given to the triceps and 1 FES treatment to the forearm all on the right side of the horse. Riding after the 3 treatments showed a reduction to Grade 1 lameness. Six weeks later the second set of treatments were given, 2 treatments were to the triceps and 1 treatment to the topline between T10-L3. Riding after the second set of treatments showed no lameness. Follow up treatments every 6-8 weeks have been continued with no further lameness.



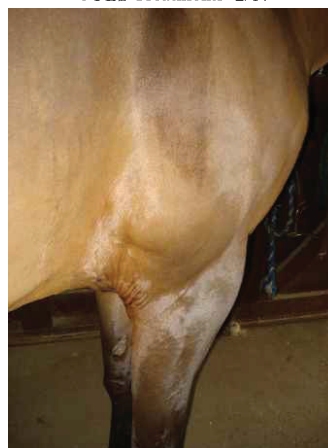Pre-FES Treatments 11/22



6 FES Treatments 2/17



Pre FES Treatments 11/22



6 FES Treatments 2/17