

EQUINEW FES 310

Clinical Cases

The clinical cases outlined are examples of injuries that have been successfully treated with FES. Specific cases were selected because they were treated exclusively with the FES modality and have documentation of the treatment progress. These examples are offered only as an overview of a specific case, which may or may not apply to another similar case. Each clinical case will provide specific issues unique to that particular horse. For further details, see www.Equinew.com under "Clinical Cases".

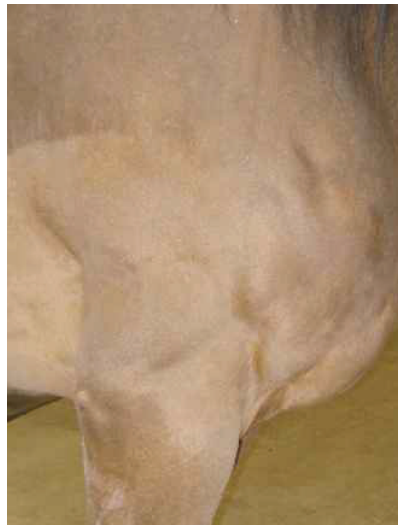"Whisper"

Aged Gelding

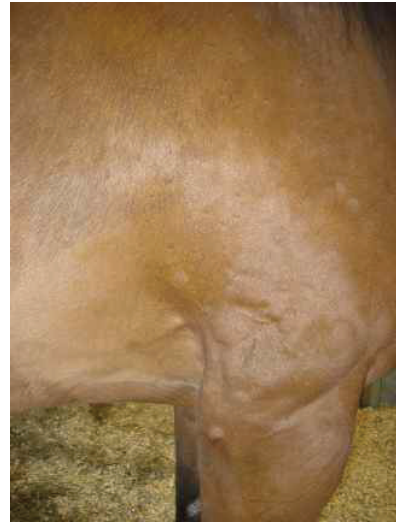
Atrophy After Ulna Fracture Surgery

9 FES Treatments on shoulder

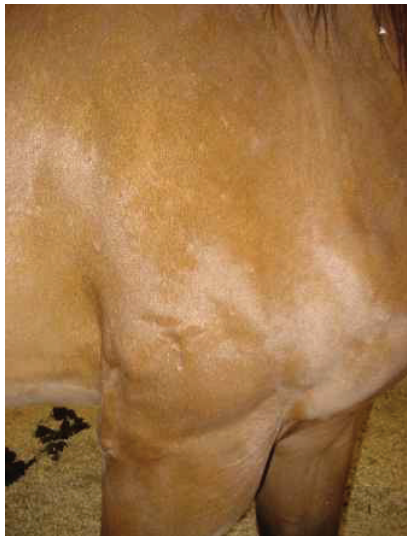3 FES Treatments on top line behind withers



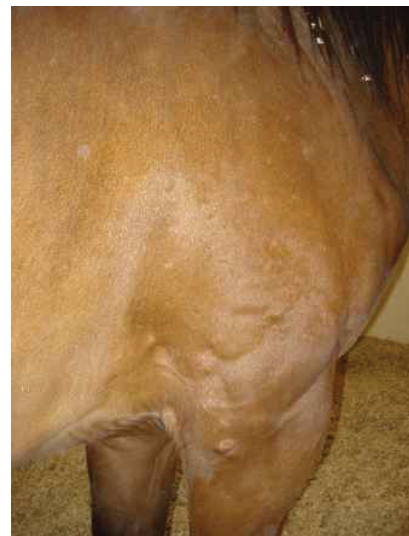
Pre Treatment



4 FES Treatments



12 FES Treatments Lateral View



12 FES Treatments Caudal View