

EQUINEW FES 310

Clinical Cases

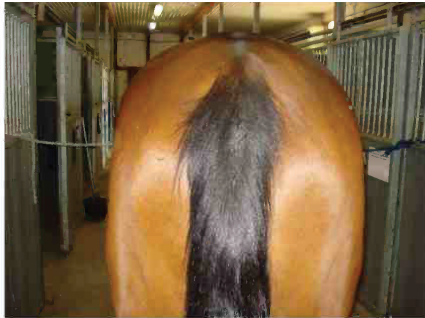Clinical cases are examples of injuries that have been successfully treated with FES. Specific cases were selected because they were treated exclusively with the FES modality and have documentation of the treatment progress. These examples are offered only as an overview of a specific case, which may or may not apply to another similar case. Each clinical case will provide specific issues unique to that particular horse.

Aged - Finnish Gelding

Severe Thoracic/Sacral Spasticity & Atrophy of Right Lumbar/Sacral

Accelerated Protocol 7 FES Treatments over 3 days 2Tx thoracic 3Tx sacral lumbar and 2Tx gluteals

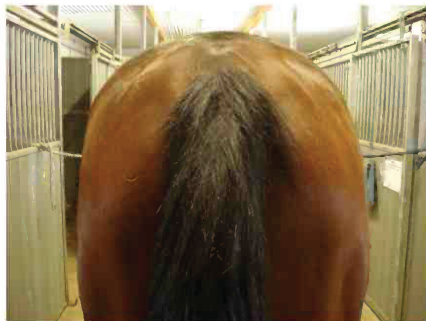SUMMARY: Upon examination the horse exhibited severe spasticity from T10 to sacrum, spasticity was more pronounced on the right. The horse was extremely sensitive to palpation and required tranquilizers for examination. The spasticity was noticeably improved after 4 treatments, (2 FES T18-S3; 1 FES T10-L4; 1 FES gluteals). As the treatments continued, the horse showed reduced spasticity and was more comfortable. After the 1st treatment, the horse did not require sedation.



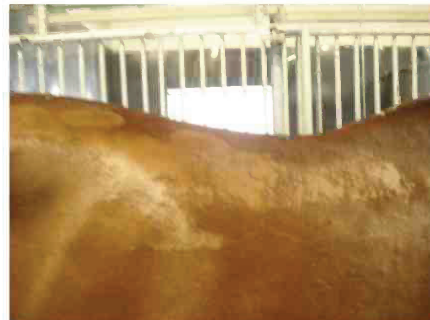July 2 Pre FES treatment



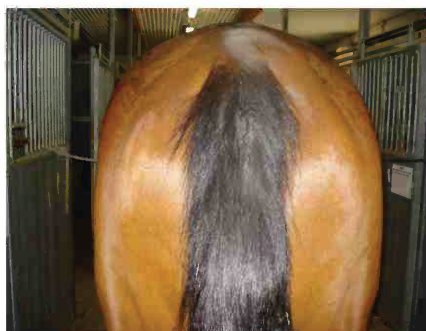
July 2 Pre FES treatment



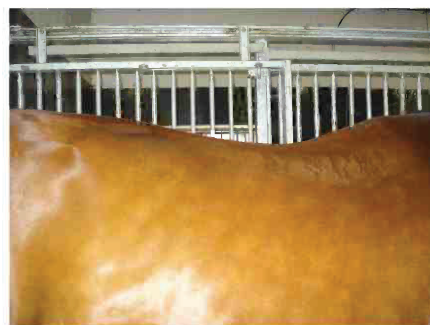July 3 After 4 FES treatments



July 3 After 4 FES treatments



July 4 After 7 FES treatments



July 4 After 7 FES treatments