

EQUINEW FES 310

Clinical Cases

Clinical cases are examples of injuries that have been successfully treated with FES. Specific cases were selected because they were treated exclusively with the FES modality and have documentation of the treatment progress. These examples are offered only as an overview of a specific case, which may or may not apply to another similar case. Each clinical case will provide specific issues unique to that particular horse.

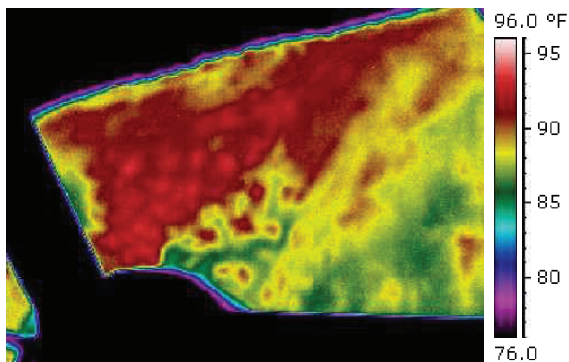
“Lou”

Aged gelding

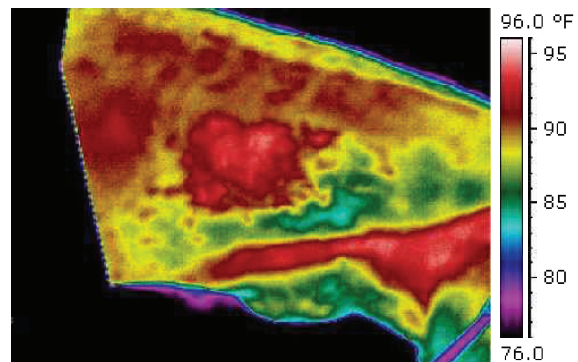
Neck Edema – Bilateral Injection Site Inflammation

1 FES Treatment

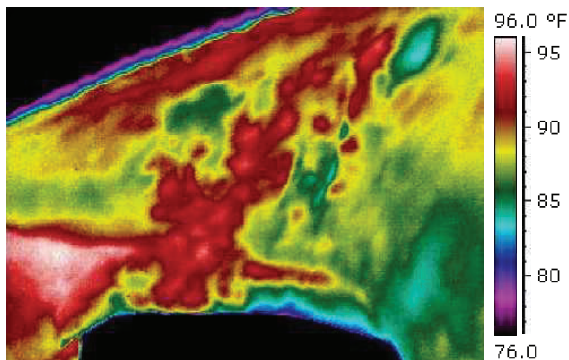
SUMMARY: Upon examination the gelding was tender and reactive to palpation of injection sites. Inflammation was due to a reaction to penicillin injections. Thermographies were taken of both injection site inflammations before treatment. One FES treatment was performed for 35 minutes. Thermographies were taken immediately after treatment and 1.5 hours after treatment. Upon removal of the FES treatment pad, there was an increase in the temperature of the neck. The temperature decreased during 1.5 hours and then displayed less heat and swelling than pre-treatment. The attending veterinarian commented that after the FES treatment the swelling was noticeably less, the horse was much more comfortable showing less tenderness in the neck, and the swelling did not return.



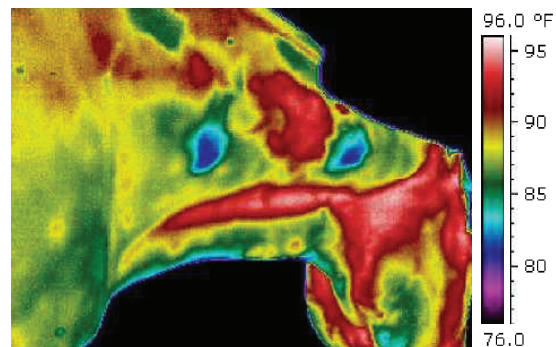
9/08 Pre-FES Treatments Left Neck



9/08 Pre-FES Treatments Right Neck



9/08 After 1 FES Treatment Left Neck



9/08 After 1 FES Treatment Right Neck